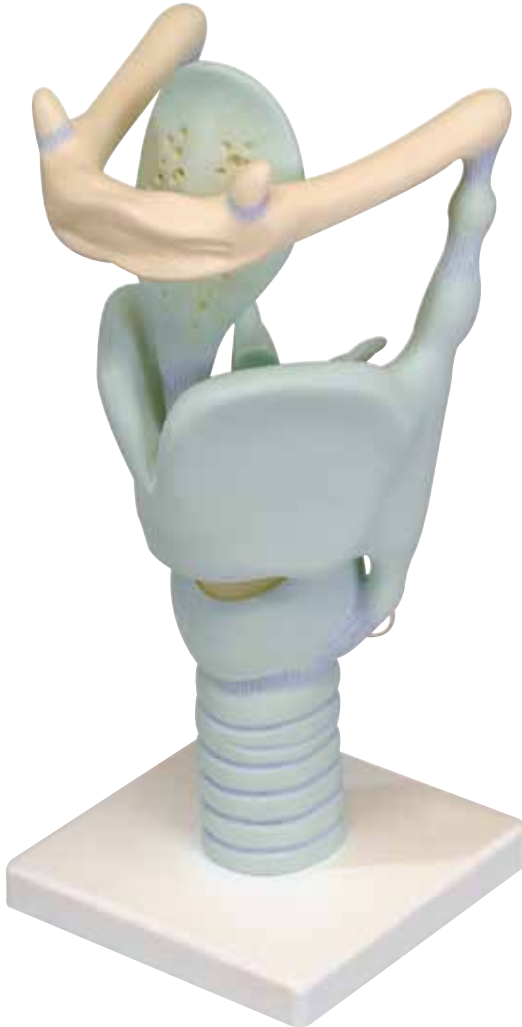



...going one step further



VC219

(1001242)

Latin

- 1 Os hyoideum
- 1a Os hyoideum, corpus
- 1b Os hyoideum, cornu minus
- 1c Os hyoideum, cornu majus
- 2 Lig. thyrohyoideum laterale
- 3 Cartilago triticea
- 4 Cartilago thyroidea
- 4a Cartilago thyroidea, lamina dextra
- 4b Cartilago thyroidea, lamina sinistra
- 4c Incisura thyroidea superior
- 4d Tuberculum thyroideum superius
- 4e Tuberculum thyroideum inferius
- 4f Cartilago thyroidea, cornu superius
- 4g Cartilago thyroidea, cornu inferius
- 5 Cartilago cricoidea
- 5a Cartilago cricoidea, arcus
- 5b Cartilago cricoidea, lamina
- 5c Facies articularis thyroidea
- 6 Cartilago arytenoidea
- 6a Cartilago arytenoidea, processus vocalis
- 6b Cartilago arytenoidea, processus muscularis
- 7 Cartilago corniculata
- 8 Cartilago epiglottica
- 9 Lig. thyroepiglotticum
- 10 Lig. vocale
- 11 Trachea, paries membranaceus
- 12 Cartilagine tracheales

Functional Larynx

English

- 1 Hyoid bone
- 1a Body of hyoid bone
- 1b Lesser horn of hyoid bone
- 1c Greater horn of hyoid bone
- 2 Lateral thyrohyoid ligament
- 3 Triticeal cartilage
- 4 Thyroid cartilage
- 4a Right lamina of thyroid cartilage
- 4b Left lamina of thyroid cartilage
- 4c Superior thyroid notch
- 4d Superior thyroid tubercle
- 4e Inferior thyroid tubercle
- 4f Superior horn of thyroid
- 4g Inferior horn of thyroid
- 5 Cricoid cartilage
- 5a Arch of cricoid cartilage
- 5b Cartilaginous lamina of cricoid
- 5c Articular surface of thyroid
- 6 Arytenoid cartilage
- 6a Vocal process of arytenoid cartilage
- 6b Muscular process of arytenoid cartilage
- 7 Corniculate cartilage
- 8 Epiglottic cartilage
- 9 Ligamentum thyroepiglotticum
- 10 Vocal ligament
- 11 Membranaceous paries of trachea
- 12 Tracheal cartilages



- 1 Zungenbein
- 1a Zungenbeinkörper
- 1b Kleines Zungenbeinhorn
- 1c Großes Zungenbeinhorn
- 2 Seitliches Schildknorpel-Zungenbeinband
- 3 Weizenkornknorpel
- 4 Schildknorpel
- 4a Schildknorpel, rechte Platte
- 4b Schildknorpel, linke Platte
- 4c Obere Schilddrüseninzisur
- 4d Schildknorpel, oberer Höcker
- 4e Schildknorpel, unterer Höcker
- 4f Schildknorpel, oberes Horn
- 4g Schildknorpel, unteres Horn
- 5 Ringknorpel
- 5a Ringknorpel, Bogen
- 5b Ringknorpel, Platte
- 5c Schildknorpel-Gelenkfläche
- 6 Stellknorpel
- 6a Stellknorpel, Stimmbandfortsatz
- 6b Stellknorpel, Muskelfortsatz
- 7 Spitzenknorpel
- 8 Kehildeckelknorpel
- 9 Kehildeckel-Schildknorpelband
- 10 Stimmband
- 11 Luftröhre, häutige Rückwand
- 12 Luftröhrenknorpel



Laringe funcional

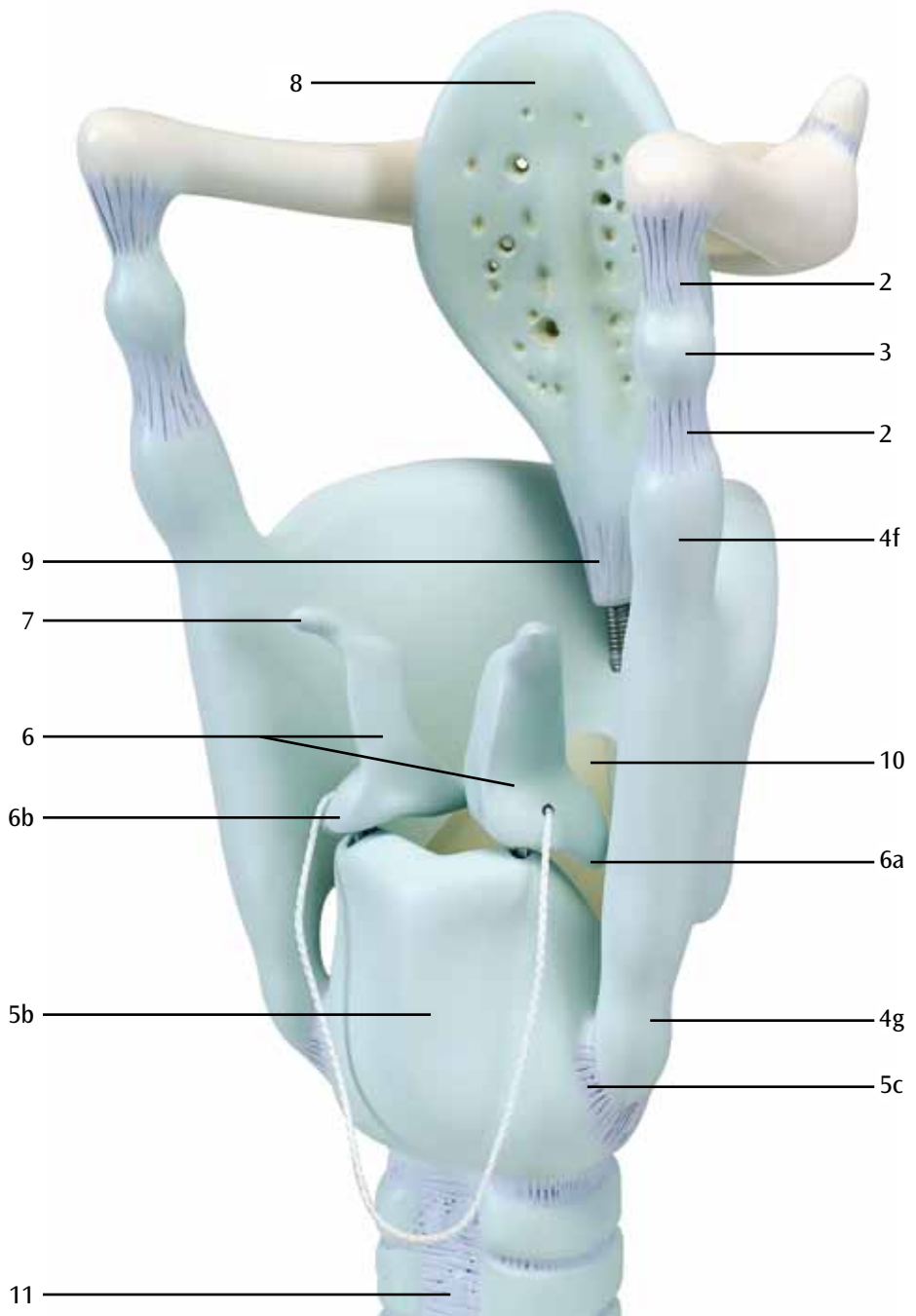
Español

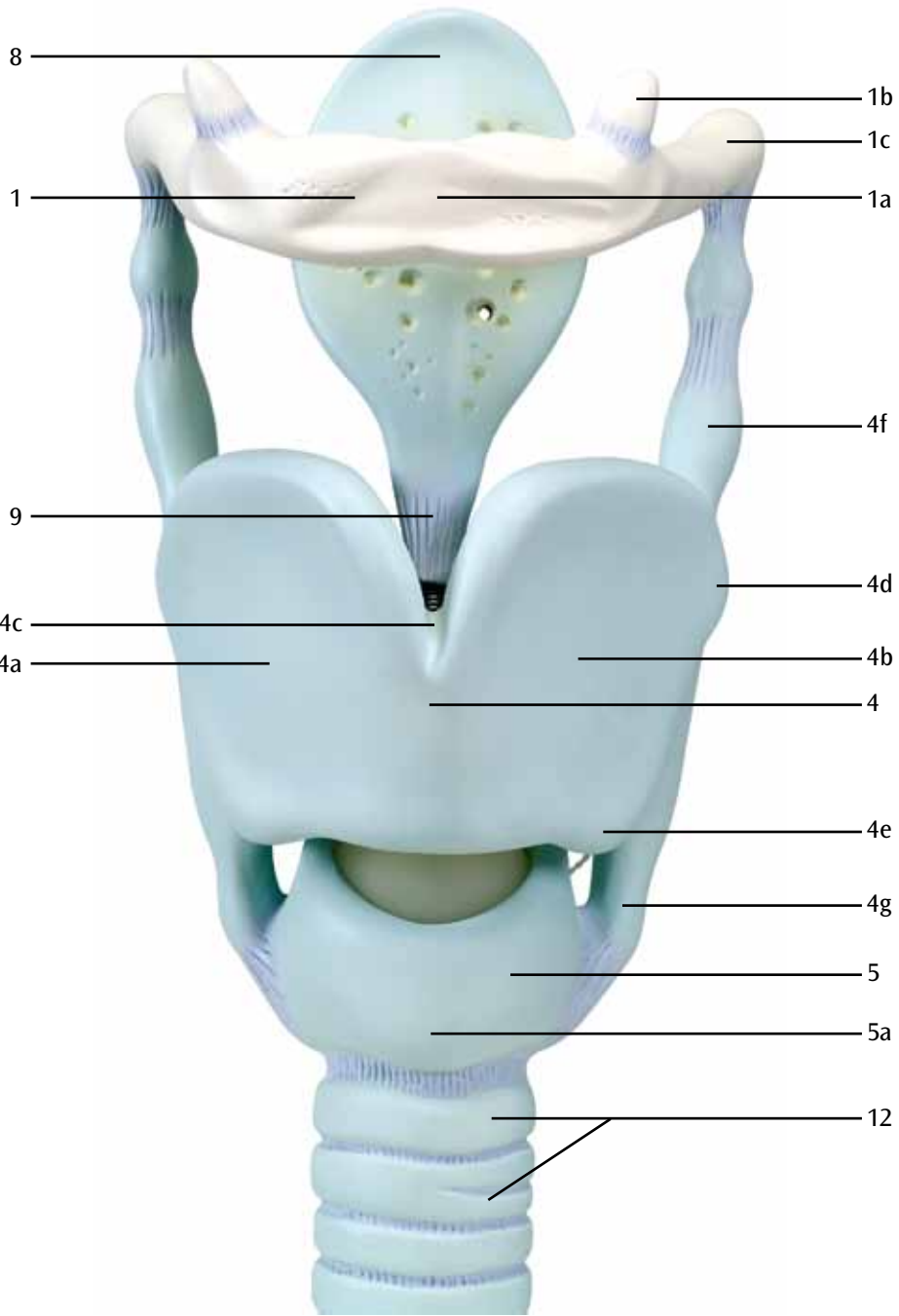
- 1 Hueso hioides
- 1a Hueso hioides, cuerpo
- 1b Hueso hioides, asta menor
- 1c Hueso hioides, asta mayor
- 2 Lig. tirohioideo lateral
- 3 Cartílago triticeo
- 4 Cartílago tiroides
- 4a Cartílago tiroideo, lámina derecha
- 4b Cartílago tiroideo, lámina izquierda
- 4c Escotadura tiroidea superior
- 4d Cartílago tiroides, tuberosidad superior
- 4e Cartílago tiroides, tuberosidad inferior
- 4f Cartílago tiroideo, asta superior
- 4g Cartílago tiroideo, asta inferior
- 5 Cartílago cricoides
- 5a Cartílago cricoides, arco
- 5b Cartílago cricoides, lámina
- 5c Cara articular tiroidea
- 6 Cartílago aritenoides
- 6a Cartílago aritenoideo, apófisis vocal
- 6b Cartílago aritenoideo, apófisis muscular
- 7 Cartílago corniculado
- 8 Cartílago de la epiglotis
- 9 Ligamento tiroepiglótico
- 10 Lig. vocal
- 11 Tráquea, porción membranosa
- 12 Cartílagos traqueales



- 1 Os hyoïde
- 1a Os hyoïde, corps
- 1b Os hyoïde, petite corne
- 1c Os hyoïde, grande corne
- 2 Ligament thyro-hyoïde latéral
- 3 Cartilage tritricé
- 4 Cartilage thyroïde
- 4a Cartilage thyroïde, lame droite
- 4b Cartilage thyroïde, lame gauche
- 4c Incisure thyroïdienne supérieure
- 4d Cartilage thyroïde, protubérance supérieure
- 4e Cartilage thyroïde, protubérance inférieure
- 4f Cartilage thyroïde, corne supérieure
- 4g Cartilage thyroïde, corne inférieure
- 5 Cartilage cricoïde
- 5a Cartilage cricoïde, arc
- 5b Cartilage cricoïde, lame
- 5c Face articulaire thyroïde
- 6 Cartilage aryténoïde
- 6a Cartilage aryténoïde, processus vocal
- 6b Cartilage aryténoïde, processus musculaire
- 7 Cartilage corniculé
- 8 Cartilage épiglottique
- 9 Ligament thyroépiglottique
- 10 Ligament vocal
- 11 Trachée, parties membraneuses
- 12 Cartilages trachéaux







Laringe funcional

Português

- 1 Osso hióide
- 1a Corpo do osso hióide
- 1b Corno menor
- 1c Corno maior
- 2 Ligamento tireoióideo lateral
- 3 Corpo tritíceo
- 4 Cartilagem tireóidea
- 4a Lâmina direita da cartilagem tireóidea
- 4b Placa esquerda da cartilagem tireóidea
- 4c Incisura tireóidea superior
- 4d Cartilagem tireóidea, tuberosidade superior
- 4e Cartilagem tireóidea, tuberosidade inferior
- 4f Corno superior da cartilagem tireóide
- 4g Corno inferior da cartilagem tireóide
- 5 Cartilagem cricóide
- 5a Arco da cartilagem cricóide
- 5b Lâmina da cartilagem cricóide
- 5c Superfície articular da tireóide
- 6 Cartilagem aritenóide
- 6a Processo vocal da cartilagem aritenóide
- 6b Processo muscular da cartilagem aritenóide
- 7 Cartilagem corniculada
- 8 Cartilagem epiglótica
- 9 Ligamento tireoepiglótico
- 10 Ligamento vocal
- 11 Parede membranosa da traquéia
- 12 Anel traqueal

- 1 Osso ioide
- 1a Osso ioide, corpo
- 1b Osso ioide, corno piccolo
- 1c Osso ioide, corno grande
- 2 Leg. tiroioideo laterale
- 3 Cartilagine triticea
- 4 Cartilagine tiroidea
- 4a Cartilagine tiroidea, lamina destra
- 4b Cartilagine tiroidea, lamina sinistra
- 4c Incisura tiroidea superiore
- 4d Cartilagine tiroidea, protuberanza superiore
- 4e Cartilagine tiroidea, protuberanza inferiore
- 4f Cartilagine tiroidea, corno superiore
- 4g Cartilagine tiroidea, corno inferiore
- 5 Cartilagine cricoidea
- 5a Cartilagine cricoidea, arco
- 5b Cartilagine cricoidea, lamina
- 5c Faccia articolare tiroidea
- 6 Cartilagine aritenoidea
- 6a Cartilagine aritenoidea, processo vocale
- 6b Cartilagine aritenoidea, processo muscolare
- 7 Cartilagine cornicolata
- 8 Cartilagine epiglottica
- 9 Legamento tiroepiglottico
- 10 Leg. vocale
- 11 Trachea, parete membranosa
- 12 Cartilagine tracheale



喉頭，3倍大ジャイアントモデル

日本語

- 1 舌骨
- 1a 舌骨体
- 1b 舌骨小角
- 1c 舌骨大角
- 2 外側甲状舌骨靭帯
- 3 麦粒軟骨
- 4 甲状軟骨
- 4a 甲状軟骨，右板
- 4b 甲状軟骨，左板
- 4c 上甲状切痕
- 4d 上甲状結節
- 4e 下甲状結節
- 4f 甲状軟骨上角
- 4g 甲状軟骨下角
- 5 輪状軟骨
- 5a 輪状軟骨弓
- 5b 輪状軟骨板
- 5c 輪状軟骨の甲状関節面
- 6 披裂軟骨
- 6a 披裂軟骨の声帯突起
- 6b 披裂軟骨の筋突起
- 7 小角軟骨
- 8 喉頭蓋軟骨
- 9 甲状喉頭蓋靭帯
- 10 声帯靭帯
- 11 気管の膜性壁
- 12 気管軟骨



- 1 Подъязычная кость
- 1a Тело подъязычной кости
- 1b Малый рог подъязычной кости
- 1c Большой рог подъязычной кости
- 2 Латеральная щитоподъязычная связка
- 3 Зерновидный хрящ
- 4 Щитовидный хрящ
- 4a Правая пластинка щитовидного хряща
- 4b Левая пластинка щитовидного хряща
- 4c Верхняя вырезка щитовидного хряща
- 4d Верхний бугорок щитовидного хряща
- 4e Нижний бугорок щитовидного хряща
- 4f Верхний рог щитовидного хряща
- 4g Нижний рог щитовидного хряща
- 5 Перстневидный хрящ
- 5a Дуга перстневидного хряща
- 5b Хрящевая пластина перстневидного хряща
- 5c Суставная поверхность щитовидного хряща
- 6 Черпаловидный хрящ
- 6a Голосовой отросток черпаловидного хряща
- 6b Мышечный отросток черпаловидного хряща
- 7 Рожковидный хрящ
- 8 Надгортанник
- 9 Щитонадгортанная связка
- 10 Голосовая складка
- 11 Мембранозная стенка трахеи
- 12 Хрящи трахеи

功能咽喉

英文

- 1 舌骨
- 1a 舌骨体
- 1b 舌骨小角
- 1c 舌骨大角
- 2 甲状舌骨侧韧带
- 3 麦粒软骨
- 4 甲状软骨
- 4a 甲状软骨右侧板
- 4b 甲状软骨左侧板
- 4c 甲状腺上切迹
- 4d 甲状腺上结节
- 4e 甲状腺下结节
- 4f 甲状腺上角
- 4g 甲状腺下角
- 5 环状软骨
- 5a 环状软骨弓
- 5b 环状软骨板
- 5c 甲状腺关节面
- 6 杓状软骨
- 6a 杓状软骨声带突
- 6b 杓状软骨肌突
- 7 小角状软骨
- 8 会厌软骨
- 9 甲状会厌韧带
- 10 声襞
- 11 气管膜壁
- 12 气管软骨



- 1 Dil kemiği (Htyoid kemiği)
- 1a Dil kemiği gövdesi
- 1b Dil kemiği küçük boynuzu
- 1c Dil kemiği büyük boynuzu
- 2 Lateral tirohiyoid bağ dokusu
- 3 Triticeal kıkırdak (Kartilaj)
- 4 Tiroid kıkırdak
- 4a Tiroid kıkırdağının sağ lamı
- 4b Tiroid kıkırdağının sol lamı
- 4c Üst tiroid çentik
- 4d Üst tiroid tüberkül
- 4e Alt tiroid tüberkül
- 4f Üst tiroid boynuzu
- 4g Alt tiroid boynuzu
- 5 Krikoid kıkırdağı
- 5a Krikoid kıkırdağı kemeri
- 5b Krikoid kıkırdaklı lam
- 5c Tiroidin oynak yüzeyi
- 6 Aritenoid kıkırdak
- 6a Aritenoid kıkırdak vokal süreç
- 6b Aritenoid kıkırdak kas süreci
- 7 Kornikulat kıkırdak
- 8 Epiglotik kıkırdak
- 9 Ligamentum trioepiglotikum
- 10 Vokal kort
- 11 Soluk borusu membran duvarı
- 12 Soluk borusu kıkırdağı



3B Scientific

A worldwide group of companies



3B Scientific GmbH

Rudorffweg 8 • 21031 Hamburg • Germany

Tel.: + 49-40-73966-0 • Fax: + 49-40-73966-100

www.3bscientific.com • 3b@3bscientific.com

© Copyright 1994 / 2005 / 2013 for instruction manual and design
of product: 3B Scientific GmbH, Germany